

Use of PRP for treatment of tibia fracture with delayed consolidation: case report

Serhii Maslennikov, Maxim Kozhemyaka

Traumatology and Orthopedics of Zaporizhzhya State Medical University, Ukraine

✉ **Serhii Maslennikov, PhD.** | travmatology1@i.ua | www.int.zsmu.edu.ua

Received | Doručené do redakcie | Doručeno do redakce 26. 7. 2022

Accepted | Prijaté po recenzii | Přijato po recenzi 18. 8. 2022

Abstract

Delayed consolidation of fractures is one of the most frequent complications in orthopedic practice. With the development of new methods of regenerative medicine, including Platelet-Rich Plasma (PRP), new possibilities for conservative treatment of this problem have emerged. This article presents a clinical case of conservative treatment of delayed consolidation of a tibial fracture using local PRP injections. In the fracture space, PRP releases various inducers of tissue growth and acting on receptors indirectly causing a chemotactic effect, mobilizes the body's own resources and create conditions for angiogenesis and trophism of injured segment. All PRP factors affect the vascular and cellular components, without which bone restoration is not possible. In the patient with delayed consolidation after PRP treatment, progress in clinical and radiological dynamics with complete healing within 1 year is noted. A positive clinical result provides a basis for further study and implementation in practice.

Keywords: tibial fractures – hypoporosis – platelet-rich plasma – osteosynthesis

Introduction

Delayed consolidation, nonunion fractures and pseudoarthrosis are a manifestation of a common problem – disorders of reparative osteogenesis of bone tissue after fractures. Disorder of bone regeneration processes after injuries of the extremities is observed in 15–18% of victims [1]. Some authors argue that the number of patients with impaired fracture consolidation reaches 25% [2,3]. The concept of “delayed consolidation” is rather relative, since the timing of fracture, healing is individual for each patient and depends on many factors. Consolidation is considered to be delayed if there are no radiological signs of callus formation at the standard time for a specific fracture location, and clinically painful and rocking movements in the fracture zone persist [4]. Despite significant advances in the surgical treatment of patients with various musculoskeletal injuries, we still try to delay surgery using all possible conservative methods.

In modern traumatology, methods of regenerative medicine, including Platelet-Rich Plasma (PRP) therapy, are relevant. PRP is an autologous product of blood with a high concentration of activated platelets, which contains platelet growth factor (PDGF), connective tissue growth factor (CTGF), vascular endothelial growth factor (VEGF), epider-

mal growth factor (EGF), insulin-like growth factors (IGF), fibroblast growth factor (FGF), keratinocyte growth factor (KGF) and transforming growth factor (TGF- β 1, TGF- β 2), that responsible for the restoration and formation of granulation tissue in the human body has become a breakthrough in stimulating and accelerating the healing of bones and soft tissues. It represents a relatively new biotechnology that is part of the growing interest in tissue engineering and cell therapy [5,6]. The rationale of PRP use for therapeutic applications is to mimic the biological healing process that normally occurs in the human body after injury. Besides, PRP shortens the different phases of the natural healing process [7,8]. PRP acts not only as a source of multiple growth factors, but also as a tridimensional bioactive scaffold, which enhances cell migration and new extracellular matrix deposition.

Case presentation

A 36-year-old female patient was admitted to our hospital after an injury caused by a fall with an emphasis on the right lower limb. On physical examination, in the projection of the middle third of the tibia, there was a subcutaneous hematoma, moderate soft tissue edema. On palpation – pathological mobility in the area of injury,

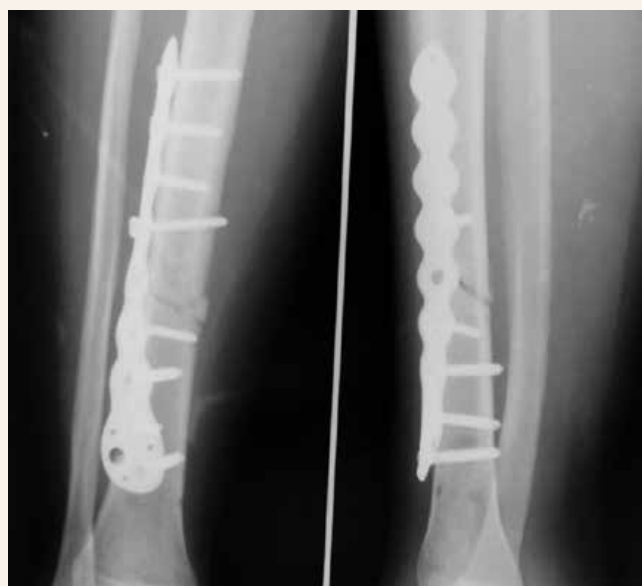crepitus of bone fragments. The support function of the injured limb is absent. Flexion in the knee and ankle joints is sharply limited due to severe pain syndrome. During the neurological examination, no disorders of the peripheral nervous system were found. The vascular surgeon excluded peripheral vascular damage. The patient underwent an X-ray examination of the right lower leg in two projections, which revealed a transverse fracture of the middle third of the tibia with displacement of fragments.

Taking into account the clinical signs, anamnesis and data of instrumental examination, the following diagnosis was made: open fracture of the right tibia in middle third with displacement of fragments, S82.1 according to ICD-10 and 42-A3 according to Müller AO.

The operation of Open Reduction Internal Fixation (ORIF) was performed using a Locking Compression Plate (LCP) plate and locking screws. During the rehabilitation period, the patient noticed intermittent severe pain in the fracture area that required a control X-ray examination, which showed the absence of the consolidation process after 4.5 months postoperatively. A fracture in the stage of delayed consolidation was diagnosed (Fig. 1).

The patient underwent three-stage injection of 4.0–4.5 ml PRP with a frequency of 10–14 days directly into the fracture area. PRP was prepared according to standard protocols, by twice spinning to obtain a final preparation with a platelet concentration in the range of 3.7–4.1 times higher than the initial values. The written informed consent of patients was obtained following a detailed explanation of the procedures that was performed.

Fig. 1 | X-ray image of the patient after 4.5 months postoperatively. X-ray signs of absence of the coalescence of bones



The procedure was carried out in a sterile operating theatre under the control of a digital C-arm monitor. After careful analgesia, the patient was injected with plasma using a 16G × 3½" needle into the fracture space, between the bone fragments (Fig. 2). The injection was performed through one approach to several points with needling and damage to scar soft tissue conglomerates.

The patient was recommended to continue conservative and physiotherapy followed by X-ray control after

Fig. 2 | Performing the PRP injection procedure into the fracture space

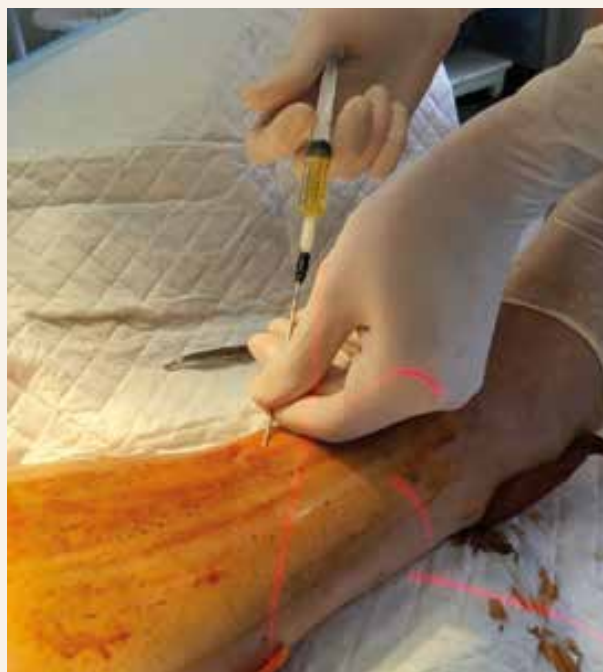
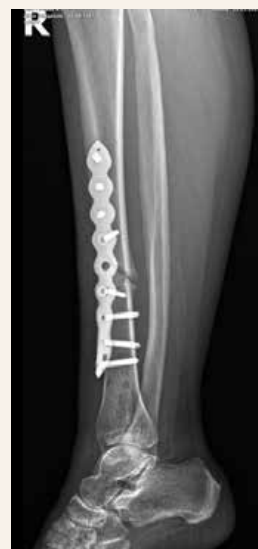
Fig. 3 | X-ray image of the injured limb after 1.5 months after the third injection. Signs of the formation of a bridge of the periosteal callus



1.5, 3 and 6 months after the third procedure. Observation of the patient continued for 1 year after the start of therapy with clinical and radiological assessment of the condition.

In 1.5 months during assessing the pain syndrome, the patient notes a decrease in pain from 7 points to 5 points according to VAS. Radiologically, the initiation of the consolidation process was noted in the form of the formation of periosteal callus on the basis of fibrocartilaginous tissue (Fig. 3).

Functionally, the patient notes an increase in the range of motion, an improvement in the support function of the lower limb.

After 3 months radiographically, the shadow of the periosteal callus is more than 1/3 of the circumference, which indicates the initiation of the consolidation process (Fig. 4).

The load on the limb in full, pain syndrome within 2–3 according to the VAS. The range of motion in the joints of the injured limb is in full, painless.

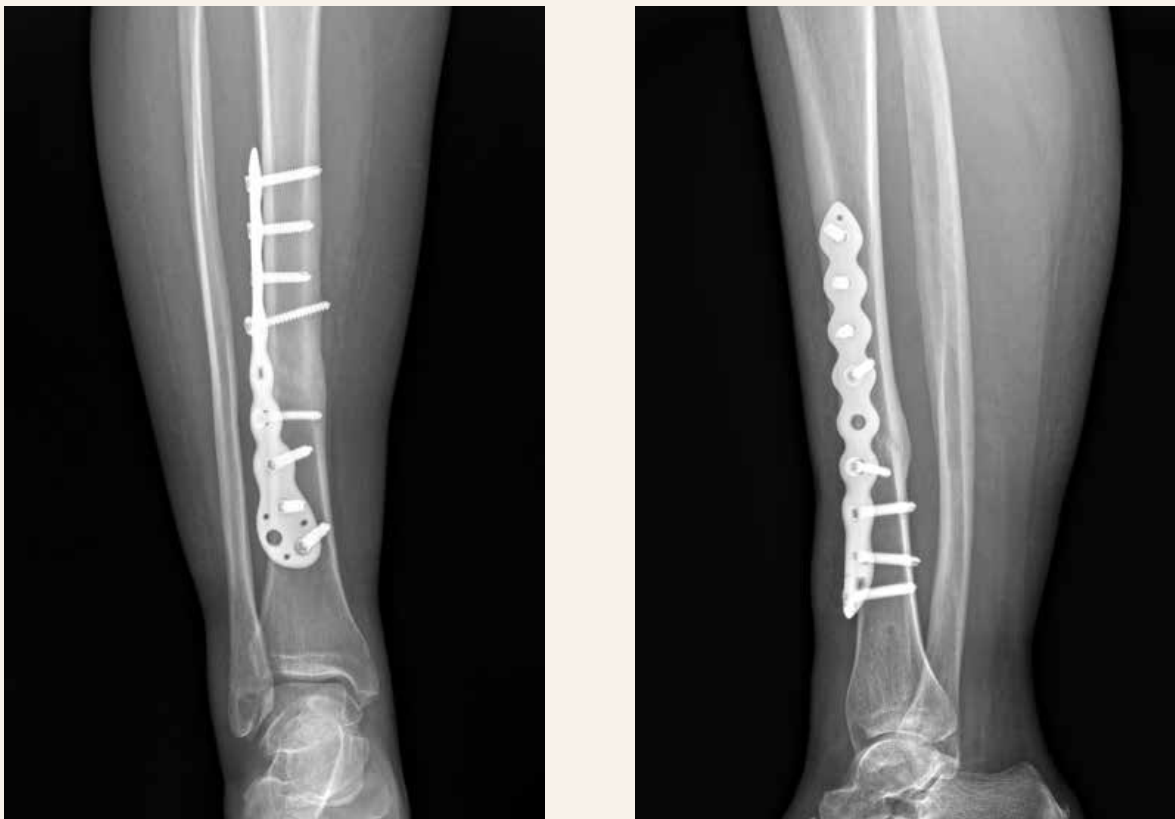
Discussion

Consolidation of long bones fractures is undoubtedly a complex biophysical and biochemical process that requires significant resources from the body and consists of many process links that can be influenced to

correct them. The process of bone repair depends on a number of general and local factors. Among the general factors, it should be noted the patient's age, physical and neuropsychiatric condition, constitution, endocrine system function, metabolism, nutrition, etc. However, in the vast majority of patients, non-union of fractures mainly depends on local factors. At first, the localization, the degree of displacement of the fragments and the type of fracture affect the rate of consolidation. The process of callus formation is significantly impaired in the presence of interposition of soft tissues covering the fracture surfaces, as well as a large hematoma between and around the fragments, since all this interferes with the deposition of bone trabeculae between the fragments, which in turn inhibits fusion. The factors listed above can be influenced by stable reduction of bone fragments, careful revision of soft tissues in the damaged area and stable fixation using available methods of internal fixation.

One of the factors in the development of this complication is the violation of bone tissue trophism. It is known that the vascularization and vitality of bone fragments are of great importance for the callus formation. Thus, any fracture of the diaphysis of the tubular bone is accompanied to a greater or lesser extent by damage to the soft tissues; in this case, the vessels and nerves

Fig. 4 | X-ray image of the injured limb after 3 months after the third injection. Signs of callus remodeling



that penetrate through the periosteum into the bone are damaged. As a result of these injuries, vascularization and trophism at the edges of the fragments are affected to a greater or lesser extent. The periosteum in the area of the fracture is also damaged by injury, exfoliates and loosens. The more damage to the feeding vessels and periosteum, the less favorable the conditions for the fusion of fragments. A mechanical effect on connective tissue scars in the fracture area, by their needling and destruction, causes local limited hemorrhage, which is a substrate for osteogenesis, and the additional administration of an increased concentration of platelets with a small number of leukocytes leads to the development of a local aseptic inflammatory reaction, which "mimics" the body about the presence of acute trauma without its actual presence. In the fracture space, PRP releases various inducers of tissue growth: FGF stimulates cell growth, synthesis of collagen and hyaluronic acid, VEGF is responsible for the growth and formation of new generations of vascular endothelial cells, TGF- β induces angiogenesis, etc [9–11]. In addition, PRP acting on receptors indirectly and causing a chemotactic effect, mobilizes the body's own resources and concentrates them in the damaged area, thus increasing the migration of mesenchymal cells to a certain area, lymphocytes, monocytes, which can have a positive effect on the activity of growth factors, since they are associated with many bioactive molecules [12]. In addition, clinical experience shows that functional healing, taking into account normal activity, occurs long before normal intraosseous architectonics is restored, and may occur before maximum strength has been achieved.

Conclusion

Local PRP therapy creates conditions for tissue repair and proliferation by activating the body's own regenerative capabilities, which is confirmed by clinical observations.

Damage to the scar tissue in combination with the use of PRP technology in the fracture area stimulates angiogenesis, improves trophism and creates the basis for the formation of callus.

The issue of the isolated effect of PRP on the process of bone tissue repair remains controversial, which requires further clinical study, but the cases of successful application give rise to thought and further search.

Highlights

- PRP therapy, along with widespread use and an impressive evidence base of action, leaves many open questions regarding the mechanisms of action and the final result.

- Isolated injection of PRP into the fracture area triggers biochemical and biophysical mechanisms that directly or indirectly stimulate the growth of callus.
- The obtained positive result of treatment is most likely associated with an increase in trophism and stimulation of cell regeneration in the damaged area under the influence of PRP factors along with the factors of general rehabilitation in the postoperative period, complementing and strengthening them.

Conflict of Interest: *The authors have no conflicts of interest to declare.*

Financial Disclosure: *The authors declared that this study has received no financial support.*

References

- Zura R, Mehta S, Della Rocca GJ et al. Biological Risk Factors for Nonunion of Bone Fracture. *JBJS Reviews* 2016; 4(1):1 e.5: 72–76. Available from DOI: <<http://doi: 10.2106/JBJS.RVW.0.00008>>.
- Nicholson JA, Makaram N, Simpson A et al. Fracture nonunion in long bones: A literature review of risk factors and surgical management. *Injury* 2021; 52 (Suppl 2): S3-S11. Available from DOI: <<http://doi: 10.1016/j.injury.2020.11.029>>.
- Lynch JR, Taitsman LA, Barei DP et al. Femoral nonunion: risk factors and treatment options. *J Am Acad Orthop Surg* 2008; 16(2): 88–97. Available from DOI: <<http://doi: 10.5435/00124635-200802000-00006>>.
- Rupp M, Biehl C, Budak M et al. Diaphyseal long bone nonunions – types, aetiology, economics, and treatment recommendations. *Int Orthop* 2018; 42(2): 247–258. Available from DOI: <<http://doi: 10.1007/s00264-017-3734-5>>.
- Roffi A, Filardo G, Kon E et al. Does PRP enhance bone integration with grafts, graft substitutes, or implants? A systematic review. *BMC Musculoskelet Disord* 2013; 14: 330. Available from DOI: <<http://doi: 10.1186/1471-2474-14-330>>.
- Marx RE, Armentano L, Olavarria A et al. Platelet-rich plasma (PRP): what is PRP and what is not PRP? *Implant Dent* 2001; 10(4): 225–228. Available from DOI: <<http://doi: 10.11607/jomi.te04>>.
- Sun Y, Feng Y, Zhang CQ et al. The regenerative effect of platelet-rich plasma on healing in large osteochondral defects. *Int Orthop* 2010; 34(4): 589–597. Available from DOI: <<http://doi: 10.1007/s00264-009-0793-2>>.
- Ghaffarparand F, Shahrezaei M, Dehghankhalili M. Effects of Platelet Rich Plasma on Healing Rate of Long Bone Non-union Fractures: A Randomized Double-Blind Placebo Controlled Clinical Trial. *Bull Emerg Trauma* 2016; 4(3): 134–140.
- Anitua E, Andia I, Ardanza B et al. Autologous platelets as a source of proteins for healing and tissue regeneration. *Thromb and Haemost* 2004; 91(1): 4–15. Available from DOI: <<http://doi: 10.1160/TH03-07-0440>>.
- Milano G, Deriu L, Sanna Passino E et al. Repeated platelet concentrate injections enhance reparative response of microfractures in the treatment of chondral defects of the knee: an experimental study in an animal model. *Arthroscopy* 2012; 28(5): 688–701. Available from DOI: <<http://doi: 10.1016/j.arthro.2011.09.016>>.
- Filardo G, Kon E, Della Villa S et al. Use of platelet-rich plasma for the treatment of refractory jumper's knee. *Int Orthop* 2009; 34(6): 909–915. Available from DOI: <<http://doi: 10.1007/s00264-009-0845-7>>.
- Dallari D, Savarino L, Stagni C et al. Enhanced tibial osteotomy healing with use of bone grafts supplemented with platelet gel or platelet gel and bone marrow stromal cells. *J Bone Joint Surg Am* 2007; 89(11): 2413–2420. Available from DOI: <<http://doi: 10.2106/JBJS.F.01026>>.